Open wedge supramalleolar osteotomy using 3D printed patient specific guides for post traumatic ankle arthritis: a case study

Presented by

Mostafa Abonnour

Abokhalifa trauma and specialized surgeries hospital , Ismailia , Egypt & IBRA fellow at Diakovere Annastift , Hannover, Germany

Supervised by

Christina Stukenborg-Colsman

Diakovere Annastift, Orthopädische Klinik der Medizinischen Hochschule Hannover, Hannover, Germany

Christian Plaass

Diakovere Annastift, Orthopädische Klinik der Medizinischen Hochschule Hannover, Hannover, Germany

Introduction:

The ankle joint is one of the most resistant joints to degenerative changes. Approximately 1 % of the adult population is affected by ankle osteoarthritis, its main etiology is post traumatic. Over time, the majority of patients with posttraumatic osteoarthritis develop tilt of talus in the ankle mortise (asymmetric ankle osteoarthritis). (1-4)

As compensatory mechanism after ankle Varus deformity, the hindfoot and subtalar joints are deformed as follows; The subtalar joint presents with compensatory deviation in intermediate stage ankle arthritis, the valgus inclination increased progressively until Stage 3a, and then decreased regressively through Stage 4. A compensatory movement of subtalar joint occurs in a varus tilted tibia or ankle. The mechanism often results in a misleading clinical appearance of neutral hindfoot alignment. This valgus subtalar joint is thought have a protective function on the progression of varus type ankle OA. (5-7).

Treatment options for early stages of post traumatic ankle osteoarthritis main goal aim to preserve the joint specially in younger patients rather than fusion. Supramalleolar tibial osteotomies are broadly the most used technique for ankle preservation surgeries.(8)

Different types of supramalleolar osteotomies for the treatment of ankle osteoarthritis are described in the literature: medial/lateral wedge osteotomies, intraarticular osteotomies, and dome osteotomies. The most common used is open wedge supramalleolar osteotomy. (9)

The deformity of distal tibia is multiplanar, current 2D-based distal tibia correction techniques can result in great variation to the desired postoperative mechanical

axis point in the ankle and require long learning curve for surgeons to attempt the desired correction. (10, 11)

The use of 3D printing-assisted supramalleolar osteotomy aims to reduce the time required for learning curve and achieve the desired multiplanar correction.

Case presentation:

A 31 years old female patient presented with ankle pain during walking. She had history of ankle fracture 10 years ago

Imaging

Standing Xray and CT ankle

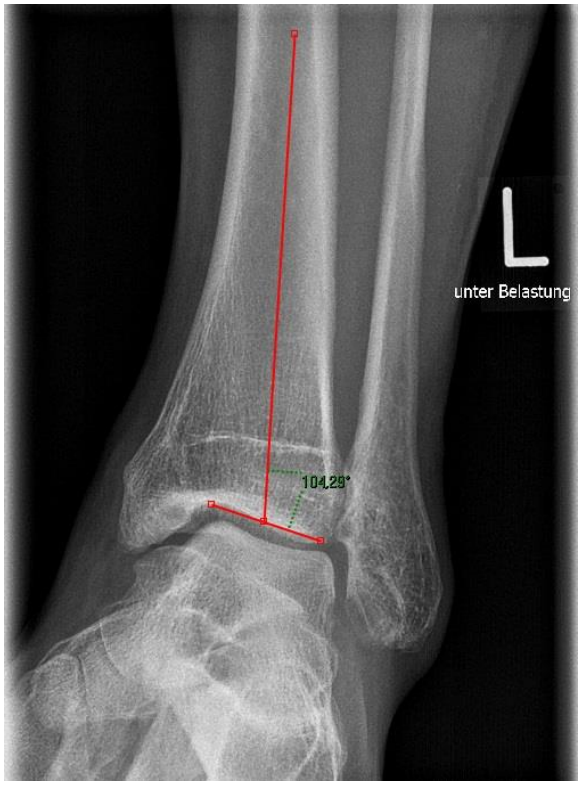

Fig (1): standing AP view of ankle shows valgus deformity of the ankle

Pre-operative planning

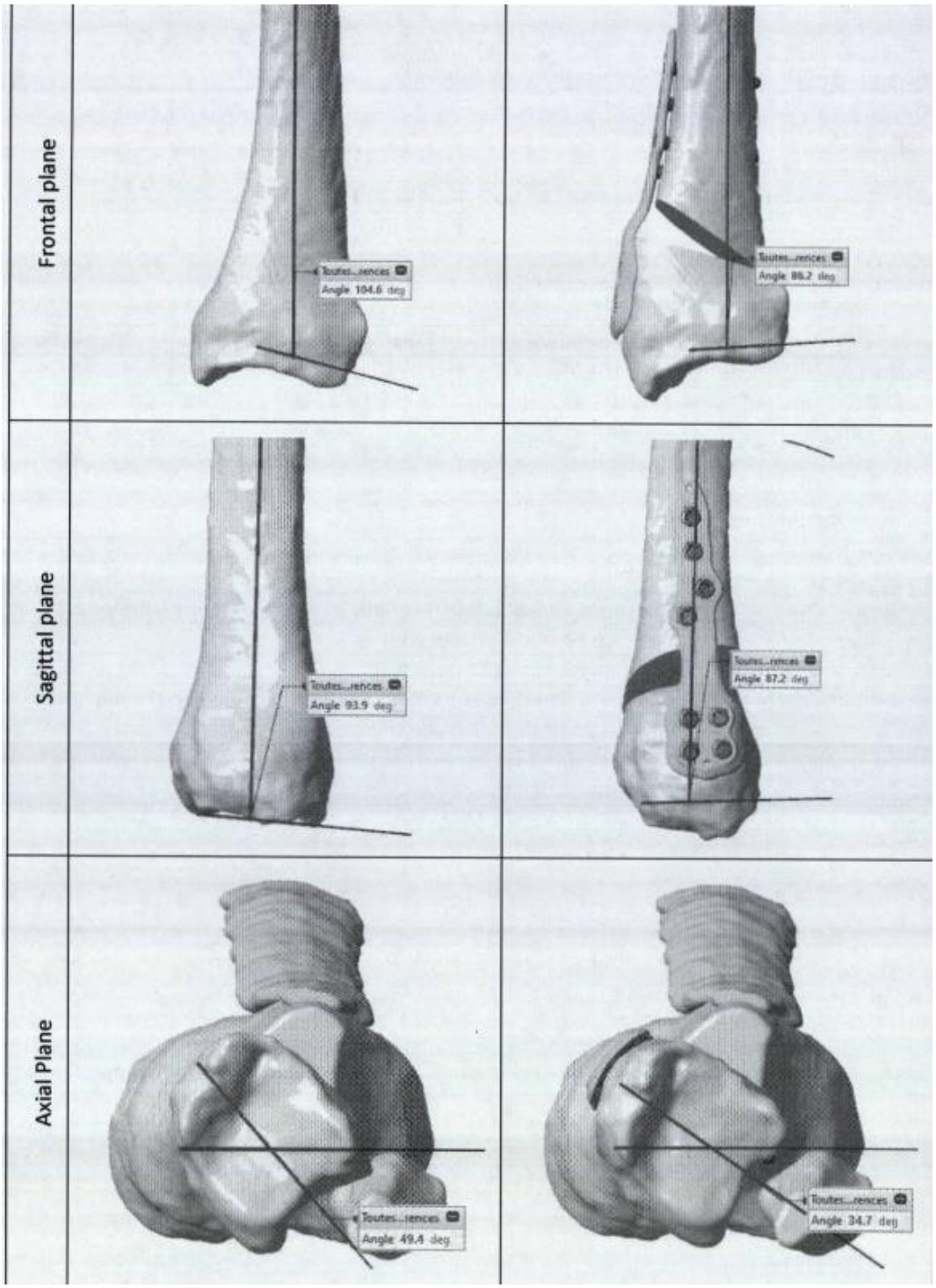

Fig (2): CT extracted measures of frontal , sagittal and axial plans on the left side and the desired correction on the left side

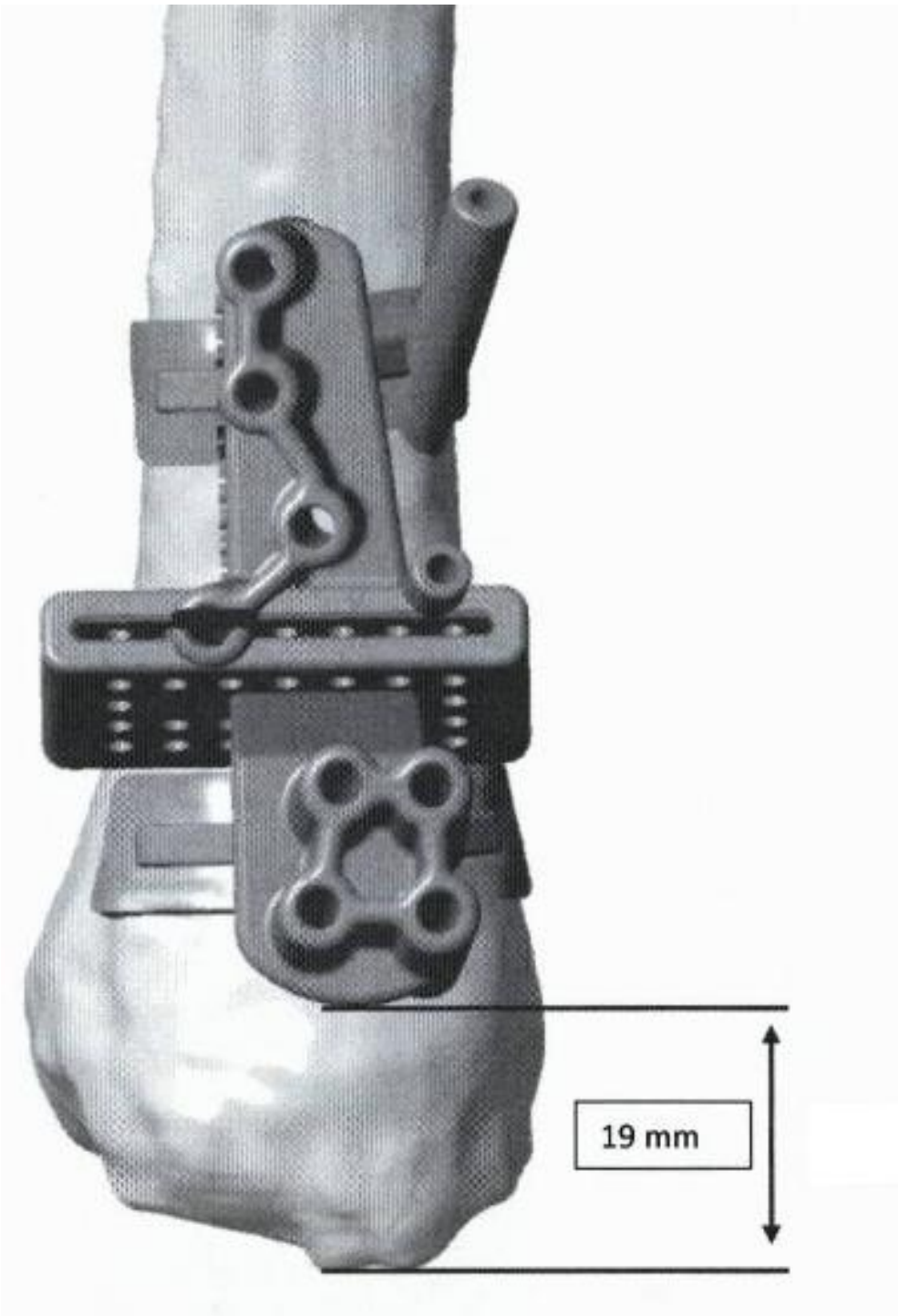

Fig(3) : supra malleolar osteotomy saw sleeve is fixed using k-wires . the desired place is identified by using sterile measure 19 mm above the tip of the most distal part of the tibia. And confirmed with image intensifier.

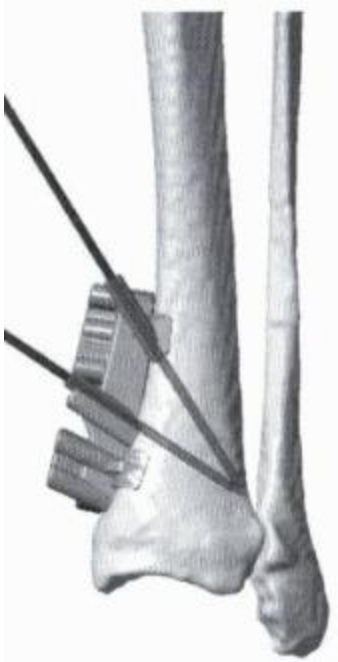

Fig 4: cutting k-wires are used to fix the saw sleeve. the apex of the wires should be 28 mm above the tip of fibula

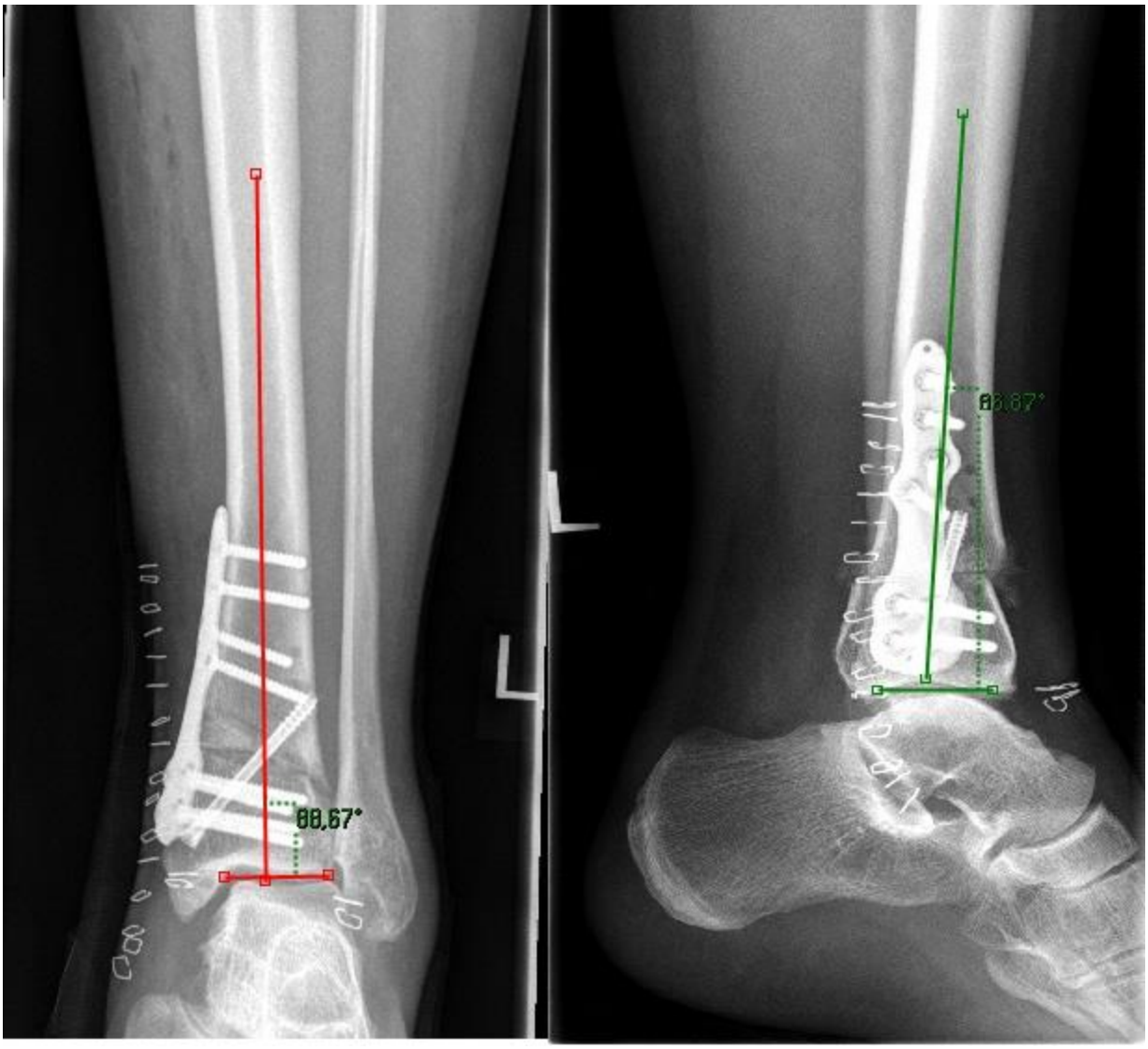

Fig (5) : post operative assessment of the frontal and sagittal plans.

Assessment of the CT and standing Xray of the patient by radiologist the following data for before and after correction:

	Preoperative	Desired	Desired correction	postoperative	Actual correction
Frontal mLDTA	104.7	86.2	18.5	88.6	16.1
Sagittal ATDA	93.9	87.2	6.7	86.8	7.1
Axial derotation	94.9	34.7	14.7		

Discussion:

The most common cause of ankle osteoarthritis is posttraumatic, which affects younger population than hip and knee osteoarthritis by 15 years. The treatment strategy in younger patients focus on ankle preserving surgeries more than arthroplasty or arthrodesis. Supramalleolar osteotomy has been proved by many studies to improve the ankle joint function, relieve the pain and delay the progression of ankle osteoarthritis (3, 9, 12, 13)

The traditional open wedge supramalleolar osteotomy has some difficulties which include :

- require long learning curve as the surgeon perform the osteotomy based on their previous experience
- repetitive adjustment of the osteotomy angle and position which lead to more bone loss , more radiation exposure and prolonged operation time.(14)

preoperative planning using 3D pre-printed models which is custom made for the patient , the surgeon can analyze deformity , precisely determine the osteotomy site and direction and it can be also be printed so that osteotomies can be performed on models minimizing the time for learning curve. (15)

when we use the 3D assisted models for osteotomy it helped us to achieve the required correction in the patient, and it helped to minimize the operation time.

Recommendations :

We would recommend that to start a randomized control trial comparing radiological and clinical short and mid term outcomes of the traditional supramalleolar osteotomy with the 3D assisted templates in treatment of posttraumatic osteoarthritis

1. Daniels T, Thomas R. Etiology and biomechanics of ankle arthritis. Foot and ankle clinics. 2008;13(3):341-52.
2. Saltzman CL, Salamon ML, Blanchard GM, Huff T, Hayes A, Buckwalter JA, et al. Epidemiology of ankle arthritis: report of a consecutive series of 639 patients from a tertiary orthopaedic center. The Iowa orthopaedic journal. 2005;25:44.
3. Bestwick-Stevenson T, Wyatt LA, Palmer D, Ching A, Kerslake R, Coffey F, et al. Incidence and risk factors for poor ankle functional recovery, and the development and progression of posttraumatic ankle osteoarthritis after significant ankle ligament injury (SALI): the SALI cohort study protocol. BMC musculoskeletal disorders. 2021;22(1):1-11.
4. Zhang S, Sun C, Zhang J, Wang Z, Zhao H, Zhang M. Changes in the subtalar joint alignment after supramalleolar osteotomy for varus ankle arthritis. Foot and Ankle Surgery. 2023;29(6):475-80.
5. Kvarda P, Heisler L, Krähenbühl N, Steiner CS, Ruiz R, Susdorf R, et al. 3D assessment in posttraumatic ankle osteoarthritis. Foot & Ankle International. 2021;42(2):200-14.
6. Hayashi K, Tanaka Y, Kumai T, Sugimoto K, Takakura Y. Correlation of compensatory alignment of the subtalar joint to the progression of primary osteoarthritis of the ankle. Foot & ankle international. 2008;29(4):400-6.
7. Kang HW, Kim D-Y, Park GY, Lee D-O, Lee DY. Coronal plane Calcaneal-Talar Orientation in Varus Ankle Osteoarthritis. Foot & Ankle International. 2022;43(7):928-36.
8. Kim J, Kim J-B, Lee W-C. Outcomes of joint preservation surgery in valgus ankle arthritis without deltoid ligament insufficiency. Foot & Ankle International. 2021;42(11):1419-30.
9. Colin F, Gaudot F, Odri G, Judet T. Supramalleolar osteotomy: techniques, indications and outcomes in a series of 83 cases. Orthopaedics & Traumatology: Surgery & Research. 2014;100(4):413-8.
10. Haraguchi N, Ota K, Tsunoda N, Seike K, Kanetake Y, Tsutaya A. Weight-bearing-line analysis in supramalleolar osteotomy for varus-type osteoarthritis of the ankle. JBJS. 2015;97(4):333-9.
11. Shi Z, Chen C, Wang C, Li X, Fu S, Wang J, et al. Open wedge supramalleolar osteotomy versus 3D printing patient-specific guides for varus ankle osteoarthritis: A retrospective case control study. 2023.
12. Chopra V, Stone P, Ng A. Supramalleolar osteotomies. Clinics in Podiatric Medicine and Surgery. 2017;34(4):445-60.

13. Butler JJ, Azam MT, Weiss MB, Kennedy JG, Walls RJ. Supramalleolar osteotomy for the treatment of ankle osteoarthritis leads to favourable outcomes and low complication rates at mid-term follow-up: a systematic review. Knee Surgery, Sports Traumatology, Arthroscopy. 2023;31(2):701-15.
14. Jastifer JR, Gustafson PA. Three-dimensional printing and surgical simulation for preoperative planning of deformity correction in foot and ankle surgery. The Journal of Foot and Ankle Surgery. 2017;56(1):191-5.
15. Zhang C, Lin Y, Yang L, Duan X. 3D Printing-Assisted Supramalleolar Osteotomy for Ankle Osteoarthritis. ACS omega. 2022;7(46):42191-8.